


## Topical treatment of equine sarcoids with imiquimod 5% cream or *Sanguinaria canadensis* and zinc chloride – an open prospective study

Carina M. Pettersson\* , Hans Broström†, Patrice Humblot† and Kerstin E. Bergvall†

\*District and Official Veterinarian, Swedish Board of Agriculture, Rådmanngatan 55, Kristinehamn, 681 34, Sweden

†Department of Clinical Sciences, University of Agriculture, Box 7054, Uppsala, 750 07, Sweden

Correspondence: Carina M. Pettersson, District and Official Veterinarian, Swedish Board of Agriculture, Rådmanngatan 55, 681 34 Kristinehamn, Sweden; Veterinary Faculty, University of Agriculture, Box 7054, 750 07 Uppsala, Sweden.

E-mail: cape1974@gmail.com

**Background** – Equine sarcoids are the most prevalent skin neoplasm in horses worldwide. Although several treatments are available, none are consistently effective and recurrence is common.

**Objectives** – To evaluate the efficacy and safety of topical imiquimod 5% cream and *Sanguinaria canadensis* + zinc chloride for treatment of equine sarcoids and investigate possible systemic effects on distant untreated sarcoids.

**Animals/Tumours** – Twenty-five client-owned horses with a total of 164 tumours were included in the study. Fifty-seven tumours were treated and 107 tumours were left untreated.

**Methods and materials** – Skin biopsy samples were collected from a minimum of one tumour per horse and the rest were diagnosed based on clinical appearance as likely sarcoids. Imiquimod 5% (A) was applied three times weekly, while *Sanguinaria canadensis* + zinc chloride (X) was applied every fourth day after a six day daily initiation phase. Treatment continued until clinical remission or for a maximum of 45 weeks, with a long follow-up period (mean 34 months). Skin biopsy samples of sarcoid lesions were re-taken before treatment termination and at follow-up if the owner gave consent.

**Results** – Complete remission was recorded in 84.4% (A) and 75.0% (X) of the tumours. Relapse was recorded in 7.3% (A) and 21.4% (X). Spontaneous remission was observed in 1.9% of untreated tumours. No systemic effect on untreated tumours was detected. During treatment varying degrees of local inflammatory reaction were common.

**Conclusions and clinical relevance** – Both treatments were considered effective and safe. Smaller tumours responded more favourably to treatment. Relapse rate was low and not observed in sarcoids with repeat biopsies before treatment termination.

### Introduction

Sarcoids are the most common skin tumours seen clinically in horses worldwide.<sup>1–4</sup> The tumours are proliferative, fibroblastic and have variable epithelial components. Most studies have shown that sarcoids rarely resolve spontaneously.<sup>1,5–8</sup> Although sarcoids are nonmetastatic, their size, spread, location, affected area and sometimes locally invasive growth can impair the use and value of the horse, and even lead to it being euthanized. The aetiology is multifactorial, including viral and genetic factors.<sup>1,2</sup> Several studies have demonstrated an association

with bovine papillomavirus (BPV types 1 and 2).<sup>9,10</sup> The bovine papillomavirus has been shown to be able to transform equine fibroblasts *in vitro*,<sup>11</sup> and the presence of BPV-DNA in surgical margins has been associated with a high rate of relapse.<sup>12,13</sup> Several treatment options are available,<sup>14–20</sup> although none is universally effective and safe. Sarcoids are well-known for a high rate of relapse post-treatment.<sup>2,6,18</sup>

Imiquimod 5% (Aldara, 3M Health Care Limited; Loughborough, UK) is an immune response modifier approved for topical use in humans, with potent antiviral and antitumour activities. Both the innate and acquired immune systems are activated via TLR7, inducing a Th1 cytokine response [interleukin (IL)-2, IL-12, interferon (IFN)- $\alpha$  and IFN- $\gamma$ ] and increases in the levels of tumour necrosis factor (TNF)- $\alpha$ , IL-1, IL-6 and IL-8. Lymphocytes, macrophages and dendritic cells are attracted to the treated area.<sup>21</sup> Successful treatment of human genital warts caused by human papillomavirus has been reported.<sup>22</sup> The drug also has been reported to be beneficial in the treatment of equine sarcoids.<sup>23</sup>

Accepted 26 May 2020

**Sources of Funding:** Xxterra was provided by N-vet AB, Uppsala, Sweden.

**Conflicts of Interest:** No conflicts of interest have been declared. Parts of the study were presented as oral short communications at the North American Veterinary Dermatology 2008 and European Society of Veterinary Dermatology 2011 annual congresses. *Vet Dermatol* 2011; 22: 466–467 (abstract).

© 2020 The Authors. Veterinary Dermatology published by John Wiley & Sons Ltd on behalf of the European Society of Veterinary Dermatology and the American College of Veterinary Dermatology, 31, 471–e126.

This is an open access article under the terms of the Creative Commons Attribution-NonCommercial License, which permits use, distribution and reproduction in any medium, provided the original work is properly cited and is not used for commercial purposes.

**Table 1.** Characteristics of the 26 horses and 167 tumours enrolled in the study

Horse	Sex	Breed	Number of sarcoids	Tumour type	Age at onset (years)	Previous treatment	Response to previous treatment
1	M	SWB	13	V, F, N, M	5	Surgery	Relapse
2	G	Standardbred	1	F	2½	None	–
3	M	SWB	7	F	NA	None	–
4	G	SWB	1	M	4	None	–
5	G	SWB	1	F	2	None	–
6	G	SWB	1	N	13	None	–
7	G	SWB	6	O, V, F, M	3	None	–
8	G	Connemara pony	28	O, N, F, M	NA	Surgery	Relapse
9*	G	SWB	3	N	12	None	–
10	G	Hanoverian	12	O, F	NA	None	–
11	G	Pony	15	F, N, O	NA	Surgery	Relapse
12	G	Icelandic horse	1	N	7	Surgery	Relapse
13	M	New Forest pony	15	O, N, M, F	3	Xxterra	Relapse
14	G	Standardbred	2	F, N	7½	Steroid	No response
15	G	Arabian	14	O, V, F, M	3	None	–
16	M	SWB	19	M, O, F, N	NA	None	–
17	G	SWB	4	O, M	NA	None	–
18	G	Arabian	6	F, O, M	8	None	–
19	G	SWB	1	M	8	None	–
20	M	SWB	1	M	NA	None	–
21	G	SWB	1	F	3	None	–
22	M	Icelandic horse	1	F	NA	None	–
23	G	Pura Raza Espanol	1	M	3	Xxterra	Relapse
24	M	Standardbred	7	N, O	12	None	–
25	G	SWB	5	N	NA	None	–
26	M	Arabian	1	N	8	None	–

Sex: M mare; G gelding.

Breed: SWB Swedish warmblood.

Tumour type: O occult, N nodular, F fibroblastic, V verrucous, M mixed type.

NA not available.

\*Excluded before treatment because histopathological evaluation revealed other diagnosis (eosinophilic granuloma).

*Sanguinaria canadensis* + zinc chloride (Xxterra, Larson Laboratories DBA Vetline Equine, Inc.; Fort Collins, CO, USA) is an unregistered herbal ointment containing a zinc chloride solution and an extract from the bloodroot plant (*Sanguinaria canadensis*). Bloodroot contains sanguinarine, chelarathrine and protopine, all of which are alkaloids. Sanguinarine has antibacterial, antifungal, anti-inflammatory and anti-platelet activities.<sup>24–27</sup> Sanguinarine also has a suppressive effect on angiogenesis,<sup>28</sup> and induces cell cycle arrest or apoptosis in mice and human cancer cells.<sup>29–32</sup> In addition, sanguinarine has been demonstrated to induce necrosis and apoptosis in KB cancer cells, which are keratin-producing tumour cells containing sequences from human papillomavirus 18 (HPV-18).<sup>33</sup> Sanguinarine interacts with DNA via intercalation, and its binding impairs DNA polymerase, inducing DNA strand breaks and cell death.<sup>34</sup> BPV, vascular endothelial growth factor (VEGF), increased angiogenesis and growth of tumour cells are strongly associated with the pathogenesis of sarcoid disease,<sup>9,10,35</sup> which presumptively make bloodroot a suitable treatment option.

The purpose of this clinical study was to evaluate the efficacy and safety of topical imiquimod 5% cream, and *Sanguinaria canadensis* + zinc chloride treatment of equine sarcoids and to investigate any possible systemic effect on distant untreated sarcoids in horses with multiple tumours.

## Methods and materials

### Ethical considerations

The study protocol was given ethical approval by the Research Animal Ethics Committee of the Swedish Board of Agriculture (no. 167/10), Uppsala, Sweden. Informed written owner consent was obtained for each case, and the owner had the right to withdraw the horse from the study at any time.

### Inclusion criteria

Client-owned horses of any breed, sex and age with one or more lesions compatible with the diagnosis of equine sarcoids were included in the study (Table 1). Biopsies of at least one tumour per horse were taken and histopathologically confirmed as a sarcoid before enrolment. Horses appeared healthy on clinical examination and were reported not to be pregnant by their owner. Before enrolment, horses had not received any sarcoid treatment, including topical and systemic corticosteroids, for at least one month. The study was advertised in different media. Horses meeting the study inclusion criteria were enrolled between March 2007 and March 2009.

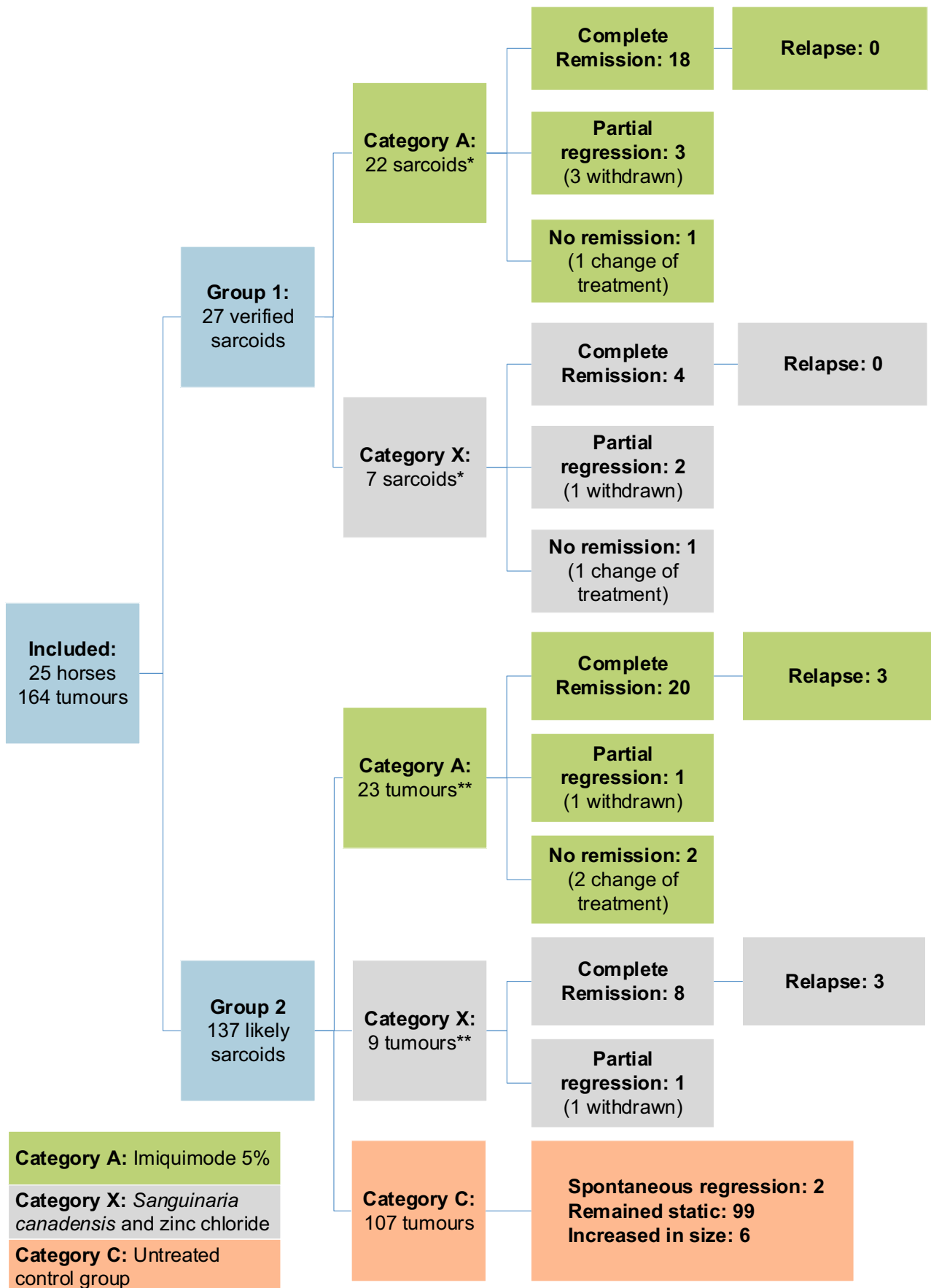
### Animals and tumours

Tumours were divided into two groups (1 or 2) according to diagnostic method:

Group 1: Histopathologically confirmed sarcoids; all treated to reduce the risk of aggressive growth after biopsy was taken.<sup>10,36–38</sup>

Group 2: Likely sarcoids based on their clinical appearance; classified according to a published clinical classification.<sup>9</sup>

The tumours then were assigned randomly (by lot drawing) to treatment Category A (Imiquimod 5%) or Category X (*Sanguinaria*



\* Tumours 1b and 10c reported in both groups A and X. \*\* Tumours 1a and 1c reported in both groups A and X

**Figure 1.** Overview of study organization of enrolment of horses and tumours into sarcoid groups, treatment categories and their treatment outcomes.

*canadensis* + zinc chloride). All facial tumours were assigned to Category A, because Xxterra is not recommended for use on the ears or in the periocular area, according to the product information and anecdotal evidence. A third category (C) was designated for tumours left untreated and used to detect potential systemic effects on distant sarcoids in horses with multiple tumours, and to determine the rate of spontaneous remission (Figure 1).

This study was nonblinded. Selection criteria for treatment (categories A or X) or allocation to Category C (left untreated) included impact of tumours on usage of the horse, location, type of sarcoid coverage and the horse owner's financial constraints. The horses were numbered consecutively and the tumours on each horse were given a letter in alphabetic order, for example, Horse 1, Tumour 1a, 1b etc. Full data on each individual tumour are available in Tables S1 and S2.

One horse with three nodular sarcoid-like lesions was excluded before treatment because histopathological evaluation revealed the presence of eosinophilic granuloma (Horse 9; Table 1).

### Treatment protocol

After the tumour was assigned to a treatment category, owners were instructed with verbal and written treatment instructions. For handling of tumours and medical products, rubber gloves were strongly recommended.

For tumours in Category A, clients were to apply a thin layer of imiquimod 5% cream topically three times weekly on nonconsecutive days.

For tumours in Category X, clients were to apply a thin layer of *Sanguinaria canadensis* + zinc chloride topically every fourth day after an initiation period of six days of daily treatment. If possible, the treated area was to be covered with a bandage. Skin surrounding the treatment area and skin that could come in contact with the treated area was protected, either with a covering or with petroleum jelly.

Tumours in both categories were cleansed with chlorhexidine digluconate 4% (Hibiscrub, Regent Medical Overseas Ltd; Irlam, UK) and dried before treatment.

Treatment period was defined as the number of weeks from the first to the last treatment of each individual tumour and continuing until complete remission (tumour mass resolved or a smooth ulcerated surface remaining) or a maximum of 45 weeks. Repeat biopsies were taken of tumours macroscopically determined to be in remission before treatment termination and at follow-up if owners consented. Biopsies were taken from the centre of the previous tumour area. Where no response to treatment was recorded after 12 weeks, the tumour was transferred to the other treatment group, after a 12-week washout period. These tumours are recorded in both treatment categories; therefore, the total number of treated tumours can exceed the number of included tumours. The treatment period was succeeded by the follow-up period, which continued until the last monitoring of the horse.

### Exclusion criteria

Histopathological diagnoses other than equine sarcoid, noncompliance with the study protocol and clients wishing to withdraw resulted in exclusion after recording the case.

### Assessment of treatment efficacy, adverse effects and follow-ups

At the first visit, information was collected on tumour description, affected relatives, age when tumour was first identified and progression of tumour growth as perceived by the owner, and previous treatments including responses to treatments. At all visits, a clinical examination of the horse was performed, and tumours were measured with a ruler (height x length x width, in mm) and photographed. Visits occurred consistently every four to six weeks during the treatment period. Owners were interviewed for compliance and possible adverse effects. Inflammatory reactions were evaluated and measured. The reaction was considered mild if swelling, erosion and crusting extended <2 cm outside the original demarcated tumour, moderate between 2 and 3 cm and severe >3 cm outside. The

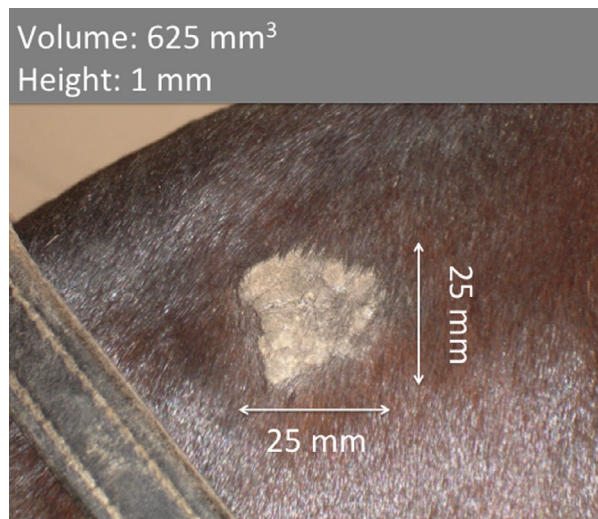


Figure 2. Small tumour (occult sarcoid, head).

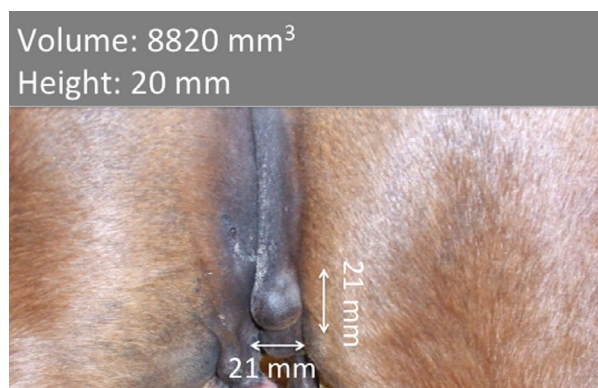


Figure 3. Medium tumour (nodular sarcoid, perineum).

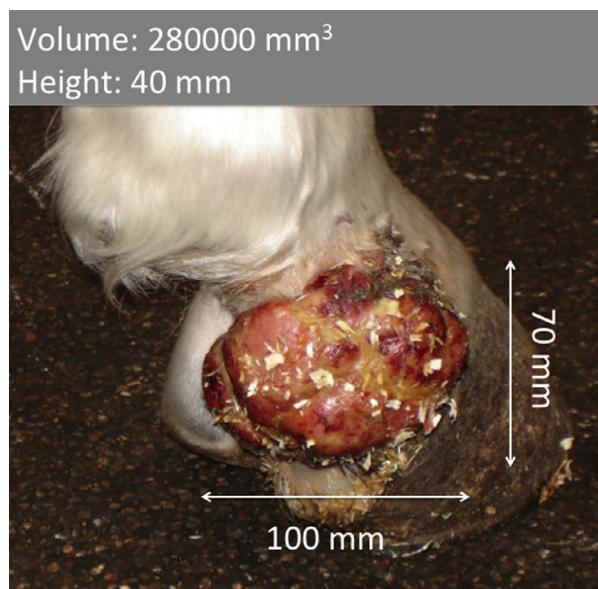


Figure 4. Large tumour (fibroblastic sarcoid, distal limb).

reaction was always considered severe if a systemic reaction occurred. If pain was reported, a nonsteroidal anti-inflammatory drug (NSAID) or a short period of treatment withdrawal (a maximum of

two weeks), were considered. Follow-up periods were between December 2007 and May 2011, and performed by re-examination or telephone interview.

### Data treatment and statistical analysis

Tumours were grouped into numbers per horse (<3, 3–10, >10); tumour size [ $<1,000 \text{ mm}^3$ , small (Figure 2);  $1,000\text{--}9,999 \text{ mm}^3$ , medium (Figure 3);  $>10,000 \text{ mm}^3$ , large (Figure 4)] and treatment duration (<10 weeks, 10–19 weeks, >19 weeks). Differences in the size of the tumours at the start (categories A and X) and at the end of the treatment period were investigated by ANOVA (proc GLM, SAS 9.2). Post ANOVA comparisons between categories were analysed using the Scheffe test. Comparisons between categories (A, X and C) were performed using the GLM contrast option, including adjustments for multiple comparisons. Similar procedures were used to test for differences in duration of treatment in relation to the treatment categories. Among treated tumours ( $n = 61$ ), the number of treatments application was compared between the categories (ANOVA). The treatment effect on changes in tumour size was evaluated by including the number of tumours, size, type and duration of treatment (three classes each) in the ANOVA model. Nonsignificant effects of factors and/or interactions were removed from the models. Finally, treatment outcome (complete remission, partial regression and no remission) was analysed by log linear models (Proc LOGISTIC, SAS 9.2), including initial number of tumours, tumour size and treatment duration (three classes each). Nonsignificant effects of factors and/or interactions were removed from the models.

For continuous variables, the results are presented as the least square means  $\pm$  standard error of the mean (SEM). Differences with associated  $P$ -values  $<0.05$  were considered significant.

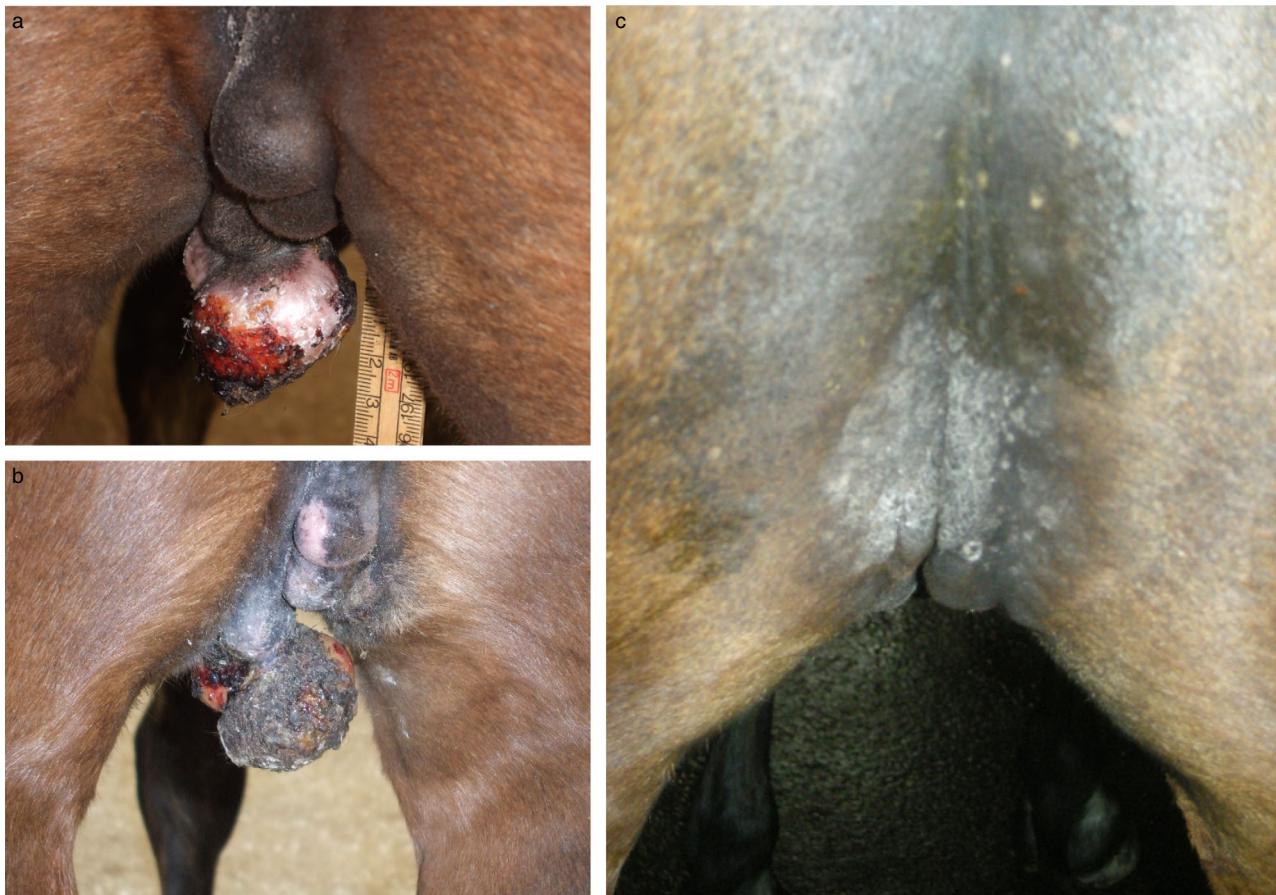## Results

### Treatment outcome

Twenty-five horses with a total of 164 tumours were included in this study (Figure 1). In total, 45 tumours were treated with imiquimod 5% cream (Category A) (Figure 5a–c), with 22 in Group 1 and 23 in Group 2. Sixteen tumours were treated with *Sanguinaria canadensis* + zinc chloride (Category X) (Figure 6a–c), seven in Group 1 and nine in Group 2. Of the 32 treated tumours in Group 2, 13% were satellite lesions and 16% were lesions within 20 cm of the tumour from which a biopsy was taken.

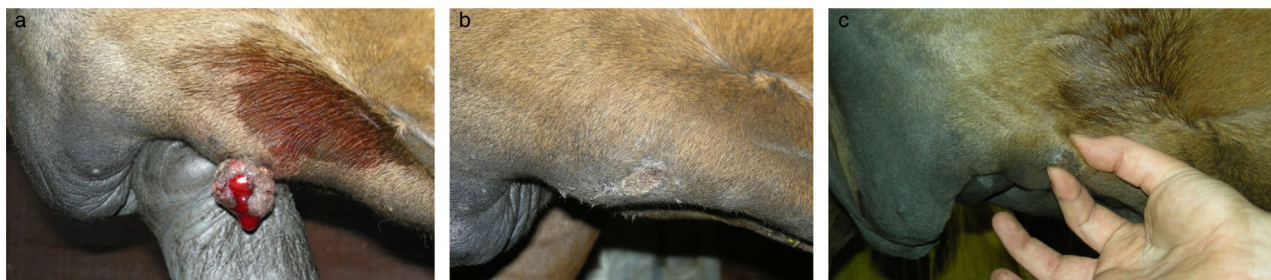After 12 weeks of treatment, three fibroblastic sarcoids (A) and one occult sarcoid (X) were regarded as non-responsive and transferred over to the other treatment category (recorded in both categories). Three tumours (1a, 1c, 10c) achieved full remission, whereas one tumour (1b) was excluded due to surgery after a 52% reduction in size. The mean volume of the three tumours in Category A (1a, 1b, 1c) were larger ( $P < 0.05$ ) than the mean volume of the tumours in categories A, X and C.

More than 50% of the tumours in Category X were large, those in Category A were more varied in size and approximately 70% in Category C were small. The pre-treatment tumour volumes were larger in categories A and X than in Category C ( $P < 0.05$ ) (Figure 7). Small

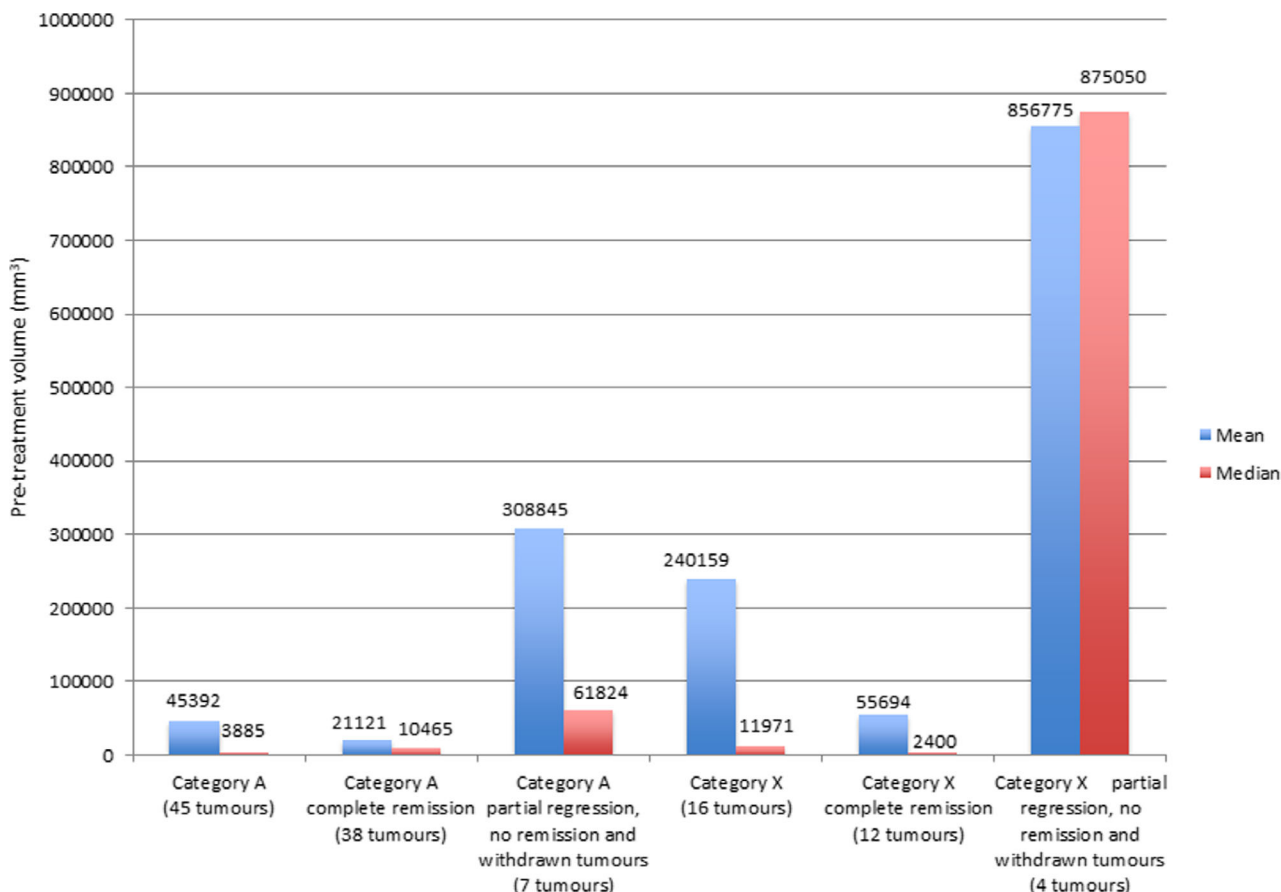


**Figure 5.** Sarcoids treated with imiquimod 5% cream.

Histopathologically verified fibroblastic and nodular sarcoids in the perineal area, before treatment (a), after five weeks of treatment (b) and at three year follow-up (c). Scar tissue is evident. Adjacent tumours also responded to treatment.



**Figure 6.** Sarcoid treated with *Sanguinaria canadensis* + zinc chloride. Histopathologically verified fibroblastic sarcoid before treatment (a), after five weeks of treatment (b) and at three year follow-up when repeat biopsy verified the clinical cure (9c). Scar tissue is evident.



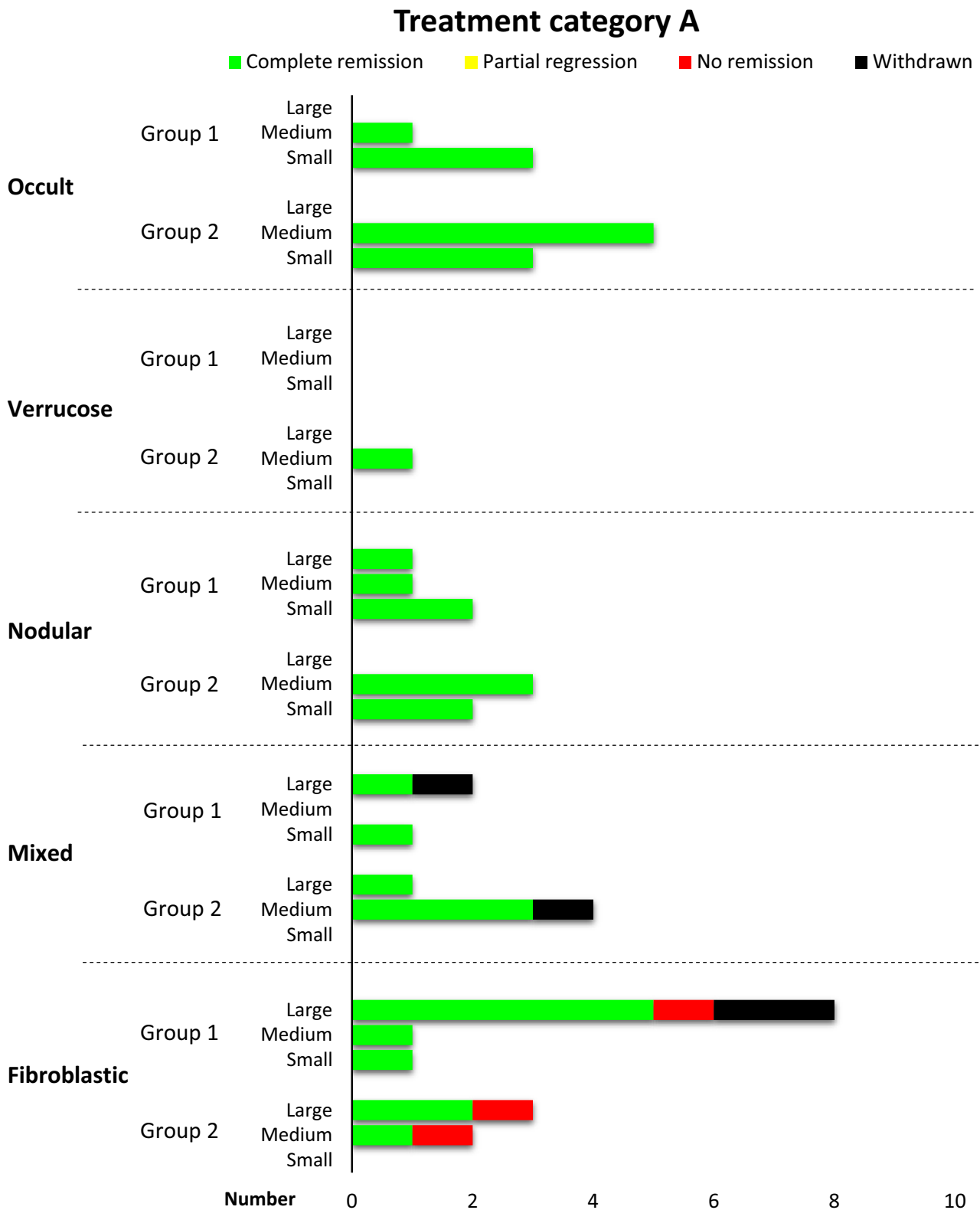
**Figure 7.** Pre-treatment mean and median tumour volume (mm<sup>3</sup>) in categories A and X.

tumours had a greater chance of complete remission than large tumours ( $P < 0.05$ ).

The treatment duration varied between four and 45 weeks (mean 16.6 weeks, median 13.5 weeks) in Category A, and between four and 38 weeks (mean 12.1 weeks, median 9.5 weeks) in Category X. Category A was composed of 12 occult, nine nodular, one verrucous, eight mixed and 15 fibroblastic sarcoids; the tumours were located on the head (27) (including six periorbital, four on the ear), axilla (four), distal limb (three), trunk (five), genitalia (five) and neck (one). Category X was composed of one occult, three nodular, two verrucous, two mixed and eight fibroblastic sarcoids, located on the limbs (five), trunk (four), genitalia (four), axilla (two) and neck (one). (Full individual tumour data, including results, are available in Tables S1 and S2). A majority of

the included horses (14 of 25) had multiple lesions (two to 28, mean 10.8, median 9.5) that were compatible with the diagnosis of being sarcoids (Table 1). In all but one horse with multiple tumours, more than one clinical type of sarcoids was present.


Complete tumour remission was recorded in 38 of 45 tumours in Category A (18 in Group 1 and 20 in Group 2) and 12 of 16 tumours in Category X (four in Group 1 and eight in Group 2) (Figures 8 and 9). In fibroblastic sarcoids complete remission was recorded in 80% with either treatment protocol. There was no difference in complete remission between the two treatment categories ( $P < 0.05$ ). Categories A and X had a higher chance of resulting in complete remission ( $P < 0.05$ ) than Category C. Treatment was the only factor that influenced remission ( $P < 0.05$ ).



**Figure 8.** Treatment Category A – type, group, size and results.

The follow-up period was eight to 200 weeks (A, mean 154 weeks, median 151 weeks; X, mean 156 weeks, median 160 weeks). Physical examination at follow-up was possible in 16 (A) and eight (X) horses. Relapse was recorded in three of 41 (A) and three of 14 (X) of the sarcoids, all in Group 2. Relapse occurred in the same area

as the original tumour. There was no difference in the relapse rate between the two treatment categories ( $P < 0.05$ ). Relapse was not detected in all sarcoids that had been re-evaluated histologically before discontinuation of treatment (seven of 55), and clinical cure could be verified by evaluation of biopsy at follow-up.



**Figure 9.** Treatment Category X – type, group, size and results.

**Withdrawn tumours**

Six of 61 tumours were withdrawn, four in Category A and two in Category X (Figure 1). There was no difference in the total number of excluded tumours in categories A and X ( $P < 0.05$ ). For four tumours, the owner chose surgical removal of the lesion after

reductions in size (16.7–89.1%) after seven to 12 weeks of treatment. One owner did not follow the treatment recommendations, and one decided to withdraw from the study as the horse rejected treatment, likely due to pain; oral NSAID treatment was offered and declined.



### Untreated sarcoids

Two (occult small) of 107 (1.9%) untreated tumours regressed spontaneously during the treatment period; thus, a reduction in tumour size was less likely ( $P < 0.05$ ) to occur in the untreated controls than in the tumours in treatment categories A and X. During the treatment period, 99 (92.5%) sarcoids remained static and six (5.6%) increased in size. In two horses with multiple tumours at inclusion, novel sarcoids (occult) developed at distant sites during the treatment period.

### Local effects

All treated areas showed signs of inflammation which were mild [38 of 45 (A), 11 of 16 (X)], moderate [four of 45 (A), three of 16 (X)] and occasionally severe [three of 45 (A), two of 16 (X)], in addition to varying degrees of oozing, exudation, erosion, crusting, swelling and pain. At follow-up, five of the horses treated with *Sanguinaria canadensis* + zinc chloride had residual scar tissue (Figure 6c), and six of the horses treated with imiquimod 5% had alopecia, two had residual scar tissue (Figure 5c) and one had hypopigmentation at the site of treatment. A temporary (two week) discontinuation of treatment was sufficient to resolve local pain in two horses; none received NSAIDs.

### Discussion

Today, there are few simple and effective treatment options available for equine sarcoids, and many of them carry a high risk of tumour relapse. This study showed promising results with a low rate of tumour relapse. Although treatments were easy to perform, they may require a long treatment period, and local pain and inflammation may occur during treatment.

The high rate of histopathological confirmation of suspected sarcoids indicates a frequent occurrence of true sarcoids, and also that clinical examination cannot fully replace histopathological evaluation. Taking a biopsy before treatment could be a risk factor for a worse prognosis, because traumatizing a sarcoid has been reported to induce more aggressive tumour growth.<sup>2,6,18</sup> Treatment was initiated promptly within 14 days for all sarcoids from which biopsies were taken. A high response rate was recorded in sarcoids from which biopsies were taken, with complete remission in 81.5% (22 of 27), including nine fibroblastic sarcoids. One fibroblastic sarcoid reduced by 98.9% in size, and four were excluded owing to surgical removal. Relapse was seen only in sarcoids that were not evaluated histologically (Group 2). Thus, taking a biopsy before treatment did not seem to result in a worse prognosis if treatment was initiated at diagnosis. In tumours from which biopsies were not taken (Group 2) there was no confirmation of the diagnosis, which may represent a weakness in this study.

An earlier study of imiquimod 5% cream in the topical treatment of equine sarcoids resulted in 56% complete remission and 20% partial regression, with mean and maximum treatment durations of 14.7 and 32 weeks, respectively.<sup>23</sup> In total, >80% of the tumours had a >75% reduction in tumour size. In the current study, complete remission was recorded in 84.4% of tumours in

treatment Category A; the higher response rate might be a consequence of the longer treatment period, with mean and maximum treatment durations of 16.6 and 45 weeks, respectively.

A retrospective questionnaire-based survey on the efficacy of Newmarket bloodroot ointment, a different formulation of bloodroot, resulted in a complete remission in 66.2% or partial regression in 20.3%. Treatment duration in that study was grouped according to total days of treatment [<21 days (63.4%); 21–42 days (26.8%); >42 days (9.8%)].<sup>39</sup> In the current study, complete remission was recorded in 75% of tumours in treatment Category X, with mean and maximum treatment duration of 12.1 and 38 weeks, possibly reflecting a different treatment protocol and longer treatment period.

Treatment was discontinued upon macroscopic evidence of curative treatment in most cases. The treatment induced visible local inflammatory reactions, which made the macroscopic assessment more difficult. A risk of both overtreatment and undertreatment of the sarcoids therefore was possible and could have introduced bias. The surrounding skin also reacted during treatment; this phenomenon was more commonly noticed in those sarcoids treated with imiquimod 5% cream. This may indicate that tumour cells and BPV outside the macroscopically demarcated tumour also were affected by the treatment, and may thus provide one explanation for the low relapse rate. Mild to moderate tenderness and pain were reported frequently when cleaning the area before treatment. This usually occurred when most of the tumour mass was gone and might reflect proximity to nerve endings in the dermis.

Small tumours responded more favourably than large tumours to any of the treatment categories. Fibroblastic tumours responded well to both treatments, with a tendency of fewer treatments in Category X. Occult tumours responded well to imiquimod 5%. As most of the occult tumours were located on the face, only one was treated with *Sanguinaria canadensis* + zinc chloride. This tumour did not respond to the treatment and was later transferred to the other treatment category. Nodular, verrucous and mixed sarcoids responded well to both treatments. No pattern in treatment outcome associated with location was detected. Interestingly, tumours that did not respond to the initial treatment (four) achieved complete remission (three) or a reduction in size (one) when they were transferred to the other treatment category. Size, type of sarcoid, location on the body and immunity may have played a role.

Less than 2% of untreated tumours (Group 2) went into spontaneous remission. Most studies have shown that sarcoids rarely resolve spontaneously.<sup>1,5–8</sup> However, a recent study in young horses (sarcoid present by the age of three years) found that 48% of milder sarcoids, occult and verrucous types, disappeared without treatment within five to seven years.<sup>40</sup> In the current study, tumours that went into spontaneous remission were occult and the horses were seven (sarcoid present by the age of three years) and six years old (no data on when sarcoids appeared) when entering the study. These two horses had multiple tumours and received treatment with both ointments. The low number of spontaneous remissions in

this study does not support the existence of a systemic effect in any of the treatment protocols.

In conclusion, in this study, both imiquimod 5% cream and *Sanguinaria canadensis* + zinc chloride were effective and safe for the topical treatment of equine sarcoids and treatments could be applied by owners without difficulty. These results are encouraging, despite the fairly small sample size, and suggest that further studies are warranted to substantiate the conclusions.

## References

1. Broström H. Equine sarcoids. A clinical and epidemiological study in relation to equine leucocyte antigens (ELA). *Acta Vet Scand* 1995; 36: 223–236.
2. Goodrich L, Gerber H, Marti E et al. Equine sarcoids. *Vet Clin North Am Equine Pract* 1998; 14: 607–619.
3. Rashmir-Raven AM. Disorders of the skin. In: Reed SM, Bayly WM, Sellon DC eds. *Equine Internal Medicine*, 4th edition. St Louis, MO: Saunders Elsevier, 2017; 1,159–1,216.
4. Ragland WL, Keown GH, Spencer GH. Equine sarcoid. *Equine Vet J* 1970; 2: 2–11.
5. Jackson C. The incidence and pathology of tumours of domestic animals in South Africa: a study of the Ondestepoort collection of neoplasms with special reference to their histopathology. *Ondestepoort J Vet Res* 1936; 6: 378–385.
6. Knottenbelt D, Edwards S, Daniel E. Diagnosis and treatment of the equine sarcoid. *InPractice* 1995; 17: 123–129.
7. Martens A, Moor ADE, Demeulemeester J et al. Histopathological characteristics of five clinical types of equine sarcoid. *Res Vet Sci* 2000; 69: 295–300.
8. Knottenbelt D. A suggested clinical classification for Equine Sarcoid. *Clin Tech Equine Pract* 2005; 4: 278–295.
9. Carr EA, Théon AP, Madewell BR et al. Bovine papillomavirus DNA in neoplastic and nonneoplastic tissues obtained from horses with and without sarcoids in the western United States. *Am J Vet Res* 2001; 62: 741–744.
10. Chambers G, Ellsmore VA, O'Brien PM et al. Association of bovine papillomavirus with the equine sarcoid. *J Gen Virol* 2003; 84: 1,055–1,062.
11. Sousa R, Dostatni N, Yaniv M. Control of papillomavirus gene expression. *Biochim Biophys Acta* 1990; 1,032: 19–37.
12. Martens A, De Moor A, Demeulemeester J et al. Polymerase chain reaction analysis of the surgical margins of equine sarcoids for Bovine Papilloma Virus DNA. *Vet Surgery* 2001; 30: 460–467.
13. Martens A, Moor ADE, Ducatelle R. PCR detection of bovine papilloma virus DNA in superficial swabs and scrapings from equine sarcoids. *Vet J* 2001; 161: 280–286.
14. Byam-Cook KL, Henson FMD, Slater JD. Treatment of periocular and non-ocular sarcoids in 18 horses by interstitial brachytherapy with iridium-192. *Vet Rec* 2006; 159: 337–341.
15. Carstanjen B, Jordan P, Lepage OM. Carbon dioxide laser as a surgical instrument for sarcoid therapy – a retrospective study on 60 cases. *Can Vet J* 1997; 38: 773–776.
16. Hewes AC, Sullins KE. Use of cisplatin-containing biodegradable beads for treatment of cutaneous neoplasia in equidae: 59 cases (2000–2004). *J Am Vet Med Assoc* 2006; 229: 1,617–1,622.
17. Lane JG. The treatment of equine sarcoids by cryosurgery. *Equine Vet J* 1977; 9: 127–133.
18. Martens A, Moor ADE, Viaminck L et al. Evaluation of excision, cryosurgery and local BCG vaccination for the treatment of equine sarcoids. *Vet Rec* 2001; 149: 665–669.
19. Théon AP, Wilson DW, Magdesian KG et al. Long-term outcome associated with intratumoral chemotherapy with cisplatin for cutaneous tumours in equidae: 573 cases (1995–2004). *J Am Vet Med Assoc* 2007; 230: 1,506–1,513.
20. Stadler S, Kainzbauer C, Haralambus R et al. Successful treatment of equine sarcoids by topical aciclovir application. *Vet Rec* 2011; 168: 187. <https://doi.org/10.1136/vr.c5430>
21. Wu J, Feldman R, Barry GT et al. Pharmacokinetics of daily self-application of imiquimod 3.75% cream in adult patients with external anogenital warts. *J Clin Pharmacol* 2012; 52: 828–836.
22. Berman B, Wolf J. The role of imiquimod 3.75% cream in the treatment of external genital warts. *Skin Therapy Lett* 2012; 17: 5–7.
23. Nogueira SA, Torres SM, Malone ED et al. Efficacy of imiquimod 5% cream in the treatment of equine sarcoids: a pilot study. *Vet Dermatol* 2006; 17: 259–265.
24. Dzik JL, Socransky SS. Comparative in vitro activity of sanguinarine against oral microbial isolates. *Antimicrob Agents Chemother* 1985; 27: 663–665.
25. Achkar IW, Mraiche F, Mohammad RM et al. Anticancer potential of sanguinarine for various human malignancies. *Future Med Chem* 2017; 9: 933–950. <https://doi.org/10.4155/fmc-2017-0041>
26. Beuria TK, Santra MK, Panda D. Sanguinarine blocks cytokinesis in bacteria by inhibiting FtsZ assembly and bundling. *Biochemistry* 2005; 44: 16,584–16,593.
27. Jeng JH, Wu HL, Lin BR et al. Antiplatelet effect of sanguinarine is correlated to calcium mobilization, thromboxane and cAMP production. *Atherosclerosis* 2007; 191: 250–258.
28. Eun JP, Koh GY. Suppression of angiogenesis by the plant alkaloid, sanguinarine. *Biochem Biophys Res Commun* 2004; 317: 618–624.
29. Ahsan H, Reagan-Shaw S, Breur J et al. Sanguinarine induces apoptosis of human pancreatic carcinoma AsPC-1 and BxPC-3 cells via modulations in Bcl-2 family proteins. *Cancer Lett* 2007; 249: 198–208.
30. Hussain AR, Al-Jomah NA, Siraj AK et al. Sanguinarine-dependent induction of apoptosis in primary effusion lymphoma cells. *Cancer Res* 2007; 67: 3,888–3,897.
31. Kim S, Lee TJ, Leem J et al. Sanguinarine-induced apoptosis: generation of ROS, down-regulation of Bcl-2, c-FLIP, and synergy with TRAIL. *J Cell Biochem* 2008; 104: 895–907.
32. Adhami VM, Aziz MH, Reagan-Shaw SR et al. Sanguinarine causes cell cycle blockade and apoptosis of human prostate carcinoma cells via modulation of cyclin kinase inhibitor-cyclin-cyclin-dependent kinase machinery. *Mol Cancer Ther* 2004; 3: 933–940.
33. Chang MC, Chan CP, Wang YJ et al. Induction of necrosis and apoptosis to KB cancer cells by sanguinarine is associated with reactive oxygen species production and mitochondrial membrane depolarization. *Toxicol Appl Pharmacol* 2007; 218: 143–151.
34. Croaker A, King GJ, Pyne JH et al. *Sanguinaria canadensis*: traditional medicine, phytochemical composition, biological activities and current uses. *Int J Mol Sci* 2016; 17: 1414. <https://doi.org/10.3390/ijms17091414>
35. Martano M, Power K, Restucci B et al. Expression of vascular endothelial growth factor (VEGF) in equine sarcoids. *BMC Vet Res* 2018; 14: 266.
36. Scott DW, Miller WH. *Equine Dermatology*, 2nd edition. Maryland Heights, MO: Saunders Elsevier, 2011; 479–488.
37. Knottenbelt DC, Kelly DF. The diagnosis and treatment of periorbital sarcoid in the horse: 445 cases from 1974 to 1999. *Vet Ophthalmol* 2000; 3: 169–191.
38. Carr EA. New developments in diagnosis and treatment of equine sarcoid. In: Robinson EN, Sprayberry K eds. *Current Therapy in Equine Medicine*, 6th edition. St Louis, MO: Saunders Elsevier, 2009; 698–702.
39. Wilford S, Woodward E, Dunkel B. Owners' perception of the efficacy of Newmarket bloodroot ointment in treating equine sarcoids. *Can Vet J* 2014; 55: 683–686.
40. Berruex F, Gerber V, Wohlfender FD et al. Clinical course of sarcoids in 61 Franches-Montagnes horses over a 5–7 year period. *Vet Q* 2016; 4: 189–196.

## Supporting Information

Additional Supporting Information may be found in the online version of this article.

Table S1. Individual tumour data and results (treatment Category A).

Table S2. Individual tumour data and results (treatment Category X).

### Résumé

**Contexte** – Les sarcoïdes équins sont la tumeur cutanée la plus prévalente chez le cheval dans le monde entier. Bien que plusieurs traitements soient disponibles, aucun n'est totalement efficace et les récurrences sont fréquentes.

**Objectifs** – Déterminer l'efficacité et l'innocuité de la crème imiquimod 5% et *Sanguinaria canadensis* + chlorure de zinc dans le traitement de sarcoïdes équins et étudier les effets systémiques potentiels sur les sarcoïdes distants non traités.

**Sujets/tumeurs** – Vingt-cinq chevaux de propriétaires avec un total de 164 tumeurs ont été inclus dans l'étude. Cinquante-sept tumeurs ont été traitées et 107 non traitées.

**Matériels et méthodes** – Des biopsies ont été prélevées, au moins une par cheval, les autres étaient diagnostiquées comme probablement des sarcoïdes à partir de l'aspect clinique. L'imiquimod 5% (A) a été appliquée trois fois par semaine, tandis que *Sanguinaria canadensis* + chlorure de zinc (X) a été appliqué tous les quatre jours après une phase d'initiation d'une fois par jour pendant six jours. Le traitement a été poursuivi jusqu'à rémission clinique ou pendant 45 semaines maximum, avec une période de suivi longue (34 mois en moyenne). Des biopsies des sarcoïdes ont été renouvelées après la fin du traitement et en suivi si le propriétaire donnait son consentement.

**Résultats** – Une rémission complète a été enregistrée dans 84.4% (A) et 75.0% (X) des tumeurs. Une récurrence a été observée dans 7.3% (A) et 21.4% (X). Une rémission spontanée a été observée dans 1,9% des tumeurs non traitées. Aucun effet systémique indésirable sur les tumeurs non traitées n'a été détecté. Au cours du traitement des degrés variables d'inflammation locale étaient fréquents.

**Conclusion et importance clinique** – Les deux traitements sont considérés comme sûrs et efficaces. Les plus petites tumeurs répondaient plus favorablement au traitement. Le taux de récurrence était faible et non observée au sein des biopsies répétées après la fin du traitement.

### Resumen

**Introducción** – los sarcoides equinos son la neoplasia cutánea más prevalente en caballos en todo el mundo. Aunque hay varios tratamientos disponibles, ninguno es eficaz de manera constante y la recidiva es frecuente.

**Objetivos** – Evaluar la eficacia y seguridad de la crema tópica de imiquimod al 5% y *Sanguinaria canadensis* + cloruro de zinc para el tratamiento de sarcoides equinos e investigar los posibles efectos sistémicos en sarcoides distantes no tratados.

**Animales/tumores** – se incluyeron en el estudio veinticinco caballos de propietarios privados con un total de 164 tumores. Se trataron cincuenta y siete tumores y se dejaron sin tratar 107 tumores.

**Métodos y materiales** – se tomaron biopsias de un mínimo de un tumor por caballo y el resto se diagnosticó basándose en la apariencia clínica como sarcoides probables. Se aplicó imiquimod al 5% (A) tres veces por semana, mientras que *Sanguinaria canadensis* + cloruro de zinc (X) se aplicó cada cuatro días después de una fase de inicio diaria de seis días. El tratamiento continuó hasta la remisión clínica o durante un máximo de 45 semanas, con un largo período de seguimiento (media de 34 meses). Se volvieron a tomar biopsias de sarcoides antes de finalizar el tratamiento y en el seguimiento si el propietario dio su consentimiento.

**Resultados** – se registró remisión completa en el 84,4% (A) y el 75,0% (X) de los tumores. Se registró recaída en el 7,3% (A) y el 21,4% (X). Se observó remisión espontánea en el 1,9% de los tumores no tratados. No se detectó ningún efecto sistémico sobre los tumores no tratados. Durante el tratamiento fueron frecuentes diversos grados de reacción inflamatoria local.

**Conclusiones y relevancia clínica** – Ambos tratamientos se consideraron efectivos y seguros. Los tumores más pequeños respondieron más favorablemente al tratamiento. La tasa de recidiva fue baja y no se observó en biopsias repetidas de sarcoides antes de finalizar el tratamiento.

### Zusammenfassung

**Hintergrund** – Equine Sarkoide sind weltweit die häufigsten Hautneoplasien bei Pferden. Obwohl einige Behandlungsformen existieren, ist keine davon gleichbleibend effektiv und ein Wiederauftreten kommt häufig vor.

**Ziele** – Eine Evaluierung der Wirksamkeit und Sicherheit von topisch angewendeter Imiquimod 5% Creme und *Sanguinaria canadensis* + Zinkchlorid zur Behandlung von equinen Sarkoiden und eine Untersuchung möglicher systemischer Wirkungen auf entfernter gelegene unbehandelte Sarkoide.

**Tiere/Tumore** – Fünfundzwanzig Pferde in Privatbesitz mit einer Gesamtzahl von 164 Tumoren wurden in die Studie aufgenommen. Fünfundsiebzig Tumore wurden behandelt und 107 Tumore blieben unbehandelt.

**Methoden und Materialien** – Es wurden Biopsien von mindestens einem Tumor pro Pferd genommen und der Rest wurde anhand des klinischen Erscheinungsbildes als wahrscheinliche Sarkoide diagnostiziert. Es wurde Imiquimod 5% (A) dreimal wöchentlich aufgetragen, während *Sanguinaria canadensis* + Zinkchlorid (X) jeden vierten Tag nach einer sechstägigen täglich aufgetragenen Eingangsphase, angewendet wurde. Die Behandlung wurde bis zur klinischen Remission oder für ein Maximum von 45 Wochen weitergeführt, mit einer langen Follow-Up Periode (durchschnittlich 34 Monate). Es wurden erneut Biopsien von Sarkoiden vor Ende der Therapie genommen und beim Follow-Up wenn der Besitzer dazu sein Einverständnis gab.

**Ergebnisse** – Es wurde bei 84,4% (A) und 75,0% (X) eine völlige Remission der Tumore festgehalten. Ein Wiederauftreten wurde bei 7,3% (A) und bei 21,4% (X) festgestellt. Es wurde bei 1,9% der unbehandelten Tumore eine spontane Remission beobachtet. Es wurde keine systemische Wirkung auf unbehandelte Tumore gesehen. Während der Behandlung traten häufig lokale entzündliche Reaktionen in unterschiedlichem Ausmaß auf.

**Schlussfolgerungen und klinische Relevanz** – Beide Behandlungen wurden als wirksam und sicher betrachtet. Kleinere Tumore reagierten besser auf die Behandlung. Die Rückfallsrate war niedrig und konnte bei den erneuten Biopsien der Sarkoide vor Ende der Behandlung nicht beobachtet werden.

## 要約

**背景** – ウマサルコイドは世界中で最も一般的な馬の皮膚腫瘍である。いくつかの治療法が利用可能であるが、どれも一貫して効果的ではなく、再発が一般的である。

**目的** – ウマサルコイド治療に対する外用イミキモド5%クリームおよび*Sanguinaria canadensis* + 塩化亜鉛の有効性および安全性を評価し、未治療のサルコイドに対する全身への影響の可能性を調査する。

**被験動物/腫瘍** – 合計164個の腫瘍を持つ25頭の顧客所有馬を研究に包含した。57個の腫瘍が治療され、107個の腫瘍が未治療のまま残された。

**材料と方法** – 生検はウマあたり最低1つの腫瘍から採取され、残りは臨床的外観に基づいてサルコイドと診断された。イミキモド5% (A) を毎週3回塗布し、*Sanguinaria canadensis* + 塩化亜鉛 (X) を開始期6日間毎日塗布の後、4日ごとに塗布した。治療は、臨床的寛解まで、または最長45週間継続され、長期追跡期間を設けた (平均34か月)。サルコイドの生検は、治療終了前および飼い主が同意した場合のフォローアップ時に再度行われた。

**結果** – 完全寛解は、腫瘍の84.4% (A) および75.0% (X) で記録された。再発は7.3% (A) と21.4% (X) で記録された。未治療の腫瘍の1.9%で自然寛解が観察された。未治療の腫瘍に対する全身的影響は検出されなかった。治療中、さまざまな程度の局所炎症反応が一般的であった。

**結論と臨床的関連性** – どちらの治療も効果的で安全であると見なされた。腫瘍が小さいほど、治療に対する反応は良好であった。再発率は低く、治療終了前のサルコイドの繰り返し生検では観察されなかった。

## 摘要

**背景** – 马肉样瘤病是全球马中最常见的皮肤肿瘤。尽管有几种治疗方法可用，但均无法持续有效，复发很常见。

**目的** – 评价外用5%咪喹莫特乳膏和加拿大血根草+氯化锌治疗马肉样瘤病的疗效和安全性，并研究对远端未治疗的肉样瘤病可能带来的全身效应。

**动物/肿瘤** – 本研究纳入了25匹私家马，总计患有164处肿瘤。57处肿瘤接受了治疗，107处肿瘤未接受治疗。

**方法和材料** – 对每匹马至少活检一个肿瘤，其余根据临床表现诊断可能为肉样瘤病。5%咪喹莫特(A)每周应用3次，而加拿大血根草+氯化锌(X)在开始阶段，连续6天每日1次，随后每4天应用1次。治疗持续至临床缓解或最长45周，长期随访 (平均34个月)。如果犬主人同意，则在治疗终止前和随访时重新活检采集肉样瘤病样本。

**结果** – 84.4%(A)和75.0%(X)的肿瘤记录为完全缓解。记录的复发率为7.3%(A)和21.4%(X)。在1.9%未治疗的肿瘤中观察到自愈。未检测到对未治疗肿瘤的全身效应。治疗期间常见不同程度的局部炎症反应。

**结论和临床相关性** – 认为两种治疗均有效且安全。较小的肿瘤对治疗的反应更好。治疗终止前重复活检的肉样瘤病，复发率低或未见复发。

## Resumo

**Contexto** – Sarcoides equinos são as neoplasias cutâneas mais prevalentes em cavalos em todo o mundo. Embora vários tratamentos estejam disponíveis, nenhum é consistentemente eficaz e a recorrência é comum.

**Objetivos** – Avaliar a eficácia e segurança do creme tópico de imiquimod 5% e *Sanguinaria canadensis* + cloreto de zinco para o tratamento de sarcoides equinos e investigar possíveis efeitos sistêmicos em sarcoides distantes não tratados.

**Animais/Tumores** – Vinte e cinco cavalos de clientes com um total de 164 tumores foram incluídos no estudo. Cinquenta e sete tumores foram tratados e 107 tumores foram deixados sem tratamento.

**Métodos e materiais** – As biópsias foram retiradas de no mínimo um tumor por cavalo e o restante foi diagnosticado com base na aparência clínica compatível com sarcoide. Imiquimod 5% (A) foi aplicado três vezes por semana, enquanto *Sanguinaria canadensis* + cloreto de zinco (X) foi aplicado a cada quatro dias após uma fase de iniciação de seis dias com uso diário. O tratamento continuou até a remissão clínica ou por um máximo de 45 semanas, com um longo período de acompanhamento (média de 34 meses). As biópsias dos sarcoides foram refeitas antes do término do tratamento e no acompanhamento, se o proprietário desse consentimento.

**Resultados** – Remissão completa foi registrada em 84,4% (A) e 75,0% (X) dos tumores. Recidiva foi registrada em 7,3% (A) e 21,4% (X). Remissão espontânea foi observada em 1,9% dos tumores não tratados. Nenhum efeito sistêmico em tumores não tratados foi detectado. Durante o tratamento, vários graus de reação inflamatória local foram comuns.

**Conclusões e relevância clínica** – Ambos os tratamentos foram considerados eficazes e seguros. Tumores menores responderam mais favoravelmente ao tratamento. A taxa de recidiva foi baixa e não observada em biópsias repetidas de sarcoides antes do término do tratamento.