

## Case Report

**Successful outcome after surgical correction of large colon atresia in a colt foal**S. Skov Hansen<sup>†</sup> , C. Matte<sup>‡</sup> , H. Treffenberg Petterson<sup>‡</sup> and M. Grabski<sup>§,\*</sup><sup>†</sup>Equine Clinic, University Animal Hospital, Swedish University of Agricultural Sciences, Uppsala, Sweden; <sup>‡</sup>Imaging Department, University Animal Hospital, Swedish University of Agricultural Sciences, Uppsala; and <sup>§</sup>Equi Vet Serwis Equine Hospital, Buk, Poland

\*Corresponding author email: milosz.grabski@yahoo.co.uk

**Keywords:** horse; atresia; colic; anastomosis; foal; congenital**Summary**

**This report describes successful surgical correction and long-term survival of a case of large colon atresia in a 24-h-old Warmblood colt, referred with signs of unrelenting abdominal pain and a suspicion of meconium impaction. Radiographic and ultrasonographic examination was indicative of large colon meconium impaction with secondary ileus. Due to deterioration of the foal, surgery was recommended. An atretic segment was found between the left ventral and dorsal large (ascending) colon. A band of fibrous tissue with no identifiable lumen connected the segments. Surgical correction was done by performing a stapled side-to-side anastomosis. Twelve days after surgery, the foal was discharged. Twenty-two months after discharge, the owner reported the foal developing as expected compared with its peers, but had a mild, self-limiting episode of colic at 20 months of age.**

**Introduction**

Intestinal atresia is a rare anomaly in foals (Bryant and Gaughan, 2005). Cases have been described with atresia in the large (ascending) colon, small colon and rectum (Schneider *et al.* 1981; Young *et al.* 1992; Nappert *et al.* 1992; Turek and Verhoeven, 2008; Biasutti *et al.* 2017). The condition has also been described in humans, calves, lambs, piglets, dogs and cats (Johnson 1986a). Three different types of atresia have been recognised based on morphologic appearance. In type 1, a normal lumen is obstructed by a membrane; in type 2, both intestinal ends are blind-ended and separated with an intact mesentery, but attached via a fibrous band; and in type 3, also called blind-end atresia, a complete absence of an intestinal segment and its associated mesentery is seen (Bryant and Gaughan, 2005). The condition is often fatal despite attempts to correct it surgically, and only a few reports of successful surgical correction exist with 6–18 months of follow-up (Schneider *et al.* 1981; Young *et al.* 1992; Nappert *et al.* 1992; Biasutti *et al.* 2017).

**Case history**

A 24-h-old Warmblood colt was referred to the Swedish University of Agricultural Sciences' Equine Hospital, with signs of unrelenting abdominal pain and a suspicion of meconium impaction. A clear passage of meconium after birth had not been ascertained, as only a small amount of light-coloured, pasty faeces had been seen. The foal developed signs of colic 12 h post-partum and was treated as a meconium

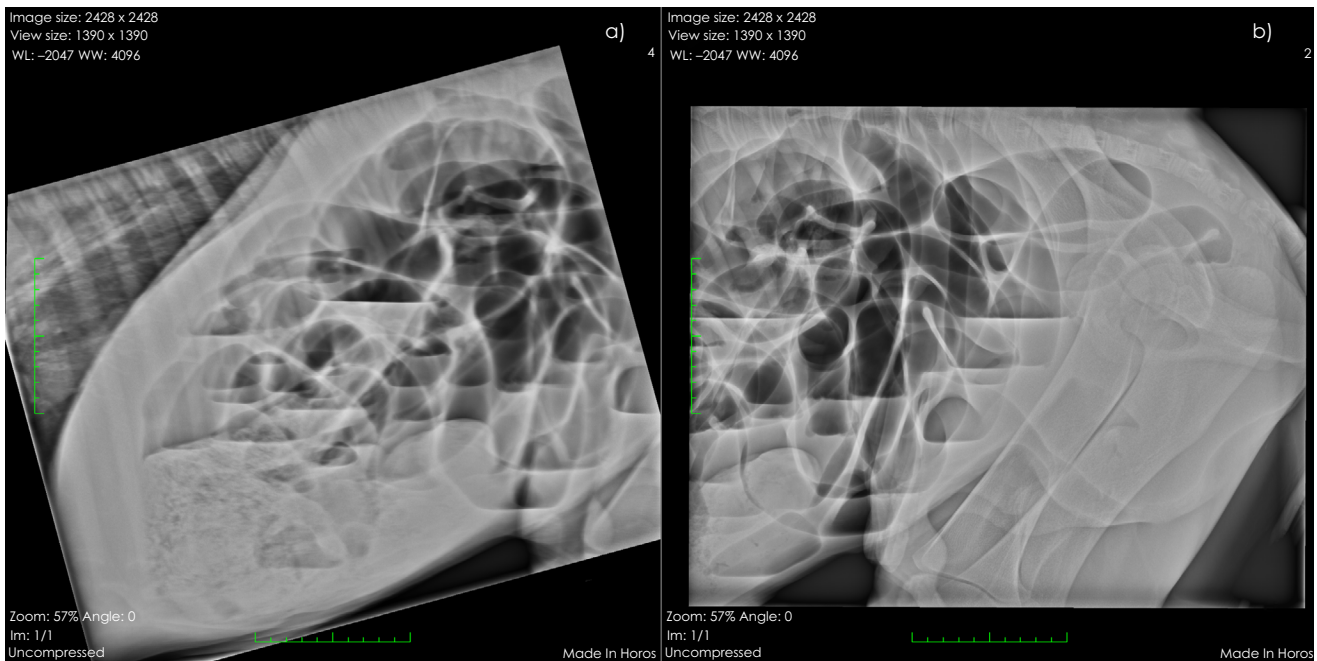
impaction by the attending veterinary surgeon, with an unsatisfactory outcome. The mare was primiparous and the foaling was reported to have been uncomplicated, and within expected gestational time. Passive immunity transfer was complete based on a normal serum IgG concentration.

**Clinical findings and treatment**

On arrival at the clinic, the foal was lethargic and showed no signs of colic. Pink mucous membranes colour, normal capillary refill time (<2 s) and the heart rate (80 beats/min) indicated normal hydration status. The abdomen was slightly distended, and the umbilicus was thickened on palpation. A digital examination of the rectum revealed no abnormalities. Standing latero-lateral abdominal radiographs (Konica Minolta DR system<sup>1</sup>) showed predominantly gas-filled, dilated (diameter greater than the length of L1) (Fischer *et al.* 1987) small intestinal loops. Fluid was observed in the small intestines, creating unequal levels, indicative of ileus. A gas-filled intestinal loop with haustra was seen in the centro-caudal abdomen, interpreted as the caecum. A large amount (25 cm length × 10 cm height) of well-formed granular soft tissue material, partly outlined by gas, was present along the ventral part of the cranial and central abdomen, extending from the area just caudal to the liver, consistent with meconium in the large colon (uncertain if in the sternal or diaphragmatic flexure; **Fig 1**).

The foal was initially treated for a severe meconium impaction. This included repeated retention enemas, analgesia with butorphanol (5 mg intravenously [i.v.], Butormidor<sup>2</sup>) and metamidol sodium (1750 mg i.v., Vetalgin vet.<sup>3</sup>), feeding via an indwelling nasogastric tube with 100 mL mare's milk every 2 h and 1 L fluid boluses of acetated Ringer's solution (Fresenius Kabi Ringer's acetate<sup>4</sup>). Prophylactic antibiotics were initiated: benzylpenicillin (12 mg/kg i.v. every 6 h Geepenil vet.<sup>5</sup>), trimethoprim/sulfadiazine (15 mg/kg i.v. every 8 h, Tribissen vet.<sup>3</sup>) along with a gastroprotectant (omeprazole 4.4 mg/kg once daily *per os*, Gastrogard<sup>6</sup>). The apparent impaction was not resolved after 24 h of treatment, and the foal displayed colic signs, had developed gastric reflux and a severely distended abdomen. Blood packed cell volume and total protein were within normal limits, and blood lactate level was 2.9 mmol/L.

Ultrasonography (LOGIQe R7<sup>7</sup>) of the abdomen showed dilated small intestines filled with mildly echogenic fluid and reduced or absent peristalsis. The large intestines contained gas and echogenic content surrounding hypoechoic



**Fig 1:** Standing latero-lateral radiograph of the cranial and mid-abdomen. A large collection of well-formed granular material is seen in the cranioventral abdomen, consistent with meconium in the large colon (a). The small intestines are gas-filled and dilated. In b) unequal fluid levels are seen. The gas-filled intestinal loop with haustrae, interpreted as caecum, is seen caudodorsally. No additional formed granular material is seen in the area of the small colon.

rounded structures. The radiological diagnosis was ileus, likely related to large intestinal obstruction due to severe meconium impaction. No obvious malformation of the large intestines was identified. Due to the progressive deterioration of the foal, exploratory celiotomy was undertaken.

### Surgery

General anaesthesia was induced with diazepam (Diazepam Ratiopharm<sup>8</sup>) and ketamine (Ketaminol<sup>3</sup>), and maintained with isoflurane (IsoFlo vet<sup>5</sup>) and oxygen in a closed circuit.

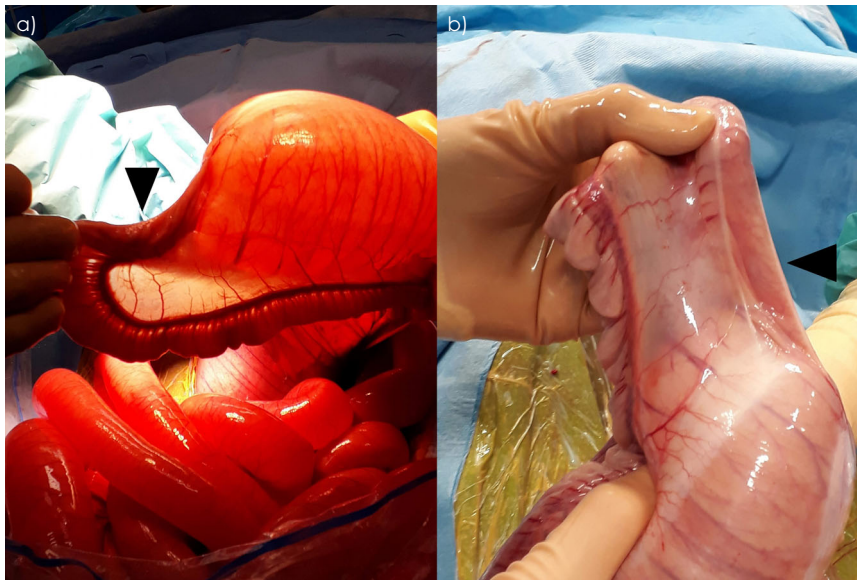
After positioning in dorsal recumbency, the ventral abdomen was prepared aseptically. The umbilical remnant was inverted and oversewn, and a second sterile preparation was performed. A midline incision was made with a fusiform incision around the umbilical remnant. The umbilical vessels and urachus were ligated using braided lactomer USP 0 (Polysorb<sup>9</sup>) and transected. The small intestines were moderately gas-distended. The caecal base and body, as well as the right and left ventral segments of the large colon, contained a large amount of meconium. An atretic segment was found between the left ventral large colon (LVC) and the left dorsal large colon (LDC), evident as a 5-cm-long band of fibrous tissue with no identifiable lumen, connecting two blind ends of colon with lumen and intact mesentery (Fig 2). The remainder of the large colon aboral to the lesion was deemed hypoplastic with a patent lumen and a diameter of approximately 3 cm, which subjectively appeared narrower than the small intestine. The LVC was decompressed using a 18G hypodermic needle. An enterotomy was performed at the most aboral aspect of the LVC adjacent to the lateral taenia, and the meconium was expelled. The enterotomy was sutured with 2 layers of a simple continuous pattern polydioxanone USP 0 (PDS<sup>10</sup>) to

minimise faecal contamination. A side-to-side anastomosis was performed between the lateral and dorsal taenia of the LVC and the lateral wall of the LDC using an anastomosis stapler (ILA-100<sup>9</sup>) with 4.8-mm staples (ILA Auto Suture 100 mm–4.8 mm<sup>9</sup>), between 10 and 20 cm oral to the enterotomy site. The LVC and LDC walls to be apposed were subjectively, 2–3 mm thick. Support for the stapled anastomosis was provided by two single interrupted polydioxanone USP 2-0 (PDS<sup>10</sup>) sutures placed to appose the seromuscular layer of LVC and LDC immediately oral to the anastomosis. The opening for the stapler was closed in two layers with polydioxanone USP 2-0 (PDS<sup>10</sup>) with a simple continuous and Cushing's patterns. The 10 cm, blind segments of the ventral and dorsal colons aboral to the new stoma were resected using the anastomotic stapler (ILA-100<sup>9</sup>; applied transversely to the long axis of the intestine) after previous ligation of the colonic vessels. Subsequently, the staple lines of the resected ends were oversewn in a Cushing pattern using polydioxanone USP 2-0 (PDS<sup>10</sup>). The anastomosed colon was lavaged with saline prior to replacing in the abdomen. The body wall was closed in three layers, and a sterile towel stent was sutured to the skin to protect the wound during anaesthetic recovery.

The post-operative care consisted of antibiotics and antacids as previously prescribed and flunixin meglumine (1.1 mg/kg once daily i.v., Flunixin N-vet<sup>11</sup>). Ringer's acetate (1 L, Fresenius Kabi Ringer's acetate<sup>4</sup>) was given every 4 h, and the foal was allowed to nurse upon return to the box.

### Immediate post-operative period

Post-operatively, the foal was ambulating well and showed no abdominal discomfort. After 24 h, the foal developed watery, fibrous diarrhoea though he continued to ambulate



**Fig 2:** (a and b) the gas-distended, ventral left large colon and atretic segment (black arrow heads) are shown. Note the small, hypoplastic, dorsal left large colon.

well. Additional treatment included anti-diarrhoeal support paste (10 mL twice daily *per os*, Diarsanyl<sup>12</sup>). Due to persisting diarrhoea, faecal sampling for rotavirus was taken over 3 consecutive days (FASTest ROTA strip<sup>13</sup>) with a negative result. Follow-up IgG test (SnapFoal<sup>14</sup>) showed an IgG concentration >8 g/L. The general condition of the foal improved gradually during hospitalisation and the severity of diarrhoea decreased. The foal was nursing well on its own within a few hours after surgery. Seven days after surgery, flunixin meglumine (Flunixin N-vet<sup>11</sup>) treatment was discontinued. The fluid boluses were decreased as the diarrhoea firmed up, and 9 days after surgery, the consistency was deemed paste-like and fluid boluses were stopped. Twelve days after surgery, skin staples were removed and the foal was discharged with instructions to continue treatment with sucralfate (1.5 g 3 times daily *per os* for 10 days, Andapsin<sup>5</sup>), procaine penicillin (20 mg/kg twice daily intramuscular for 5 days, Ethacilin vet.<sup>3</sup>) and trimethoprim/sulfadiazine (15 mg/kg twice daily *per os* for 10 days, Hippotrim vet.<sup>15</sup>).

## Diagnosis

Based on clinical and surgical findings, the foal was diagnosed with congenital type 2 colonic atresia.

## Outcome

Twenty-two months after discharge, the owner reported that the foal's development was as expected compared with its peers, but it suffered a mild, self-limiting episode of colic at 20 months of age. Due to limited availability of grass during the first summer, the foal's diet had been supplemented with hay during much of the follow-up period.

## Discussion

Intestinal atresia is a rare abnormality in foals and is often associated with a poor prognosis despite attempts to correct

it surgically. It has a reported occurrence rate of 0.45–1.3% (Young *et al.* 1992; Nappert *et al.* 1992), with the large colon and pelvic flexure being the most commonly affected segments, followed by the transverse and small colon (Young *et al.* 1992; Nappert *et al.* 1992; Turek and Verhoeven, 2008). Presence of other congenital abnormalities influences prognosis negatively (Young *et al.* 1992; Nappert *et al.* 1992). In the few cases of successful treatment of intestinal atresia in foals (Estes and Lyall, 1979; Schneider *et al.* 1981; Biasutti *et al.* 2017), follow-up is relatively short. Estes and Lyall (1979) reported that the treated individual was doing well 1.5 year post-operatively, and Biasutti *et al.* (2017) had 6 months of follow-up without complications. In our case, the foal was developing as expected 22 months after discharge, despite a mild, self-limiting colic episode at 20 months of age. This could suggest a more positive prognosis if surgical correction is successful, and the foal survives to discharge.

The aetiology of colon atresia in foals is not well understood. Suggested causes include imperfect recanalisation, vascular accidents, genetic factors and persistent anal membrane (Louw 1964; Johnson 1986a; Johnson 1986b). A study performed by Louw (1964) supports the theory of vascular accidents. When ligating the mesenteric vascular supply at different levels, type 1 and type 2 atresia could be reproduced, but when mimicking a strangulating lesion of the small intestines, a type 3 atresia was observed. In cattle, pressure exerted on rectal palpation of the embryo until day 45 was assumed to increase the risk of development of intestinal atresia (Schlegel *et al.* 1986); however, recent studies in dairy cattle did not observe any effects of pregnancy diagnosis done by rectal palpation in the late embryonic period (Romano *et al.* 2016; Romano *et al.* 2017). A hereditary trait cannot be excluded, as gene mutations have been discovered in calves suffering from/subjected to euthanasia due to multiple congenital atresias, as well as in their parents, when compared to controls (Samuels *et al.* 2013). Whether a genetic component exists in horses requires further investigation of both afflicted

foals and their parental lines. Given existing evidence in other species, we recommended against any future use for breeding in the described case, and advised castration of the colt in the future.

Foals suffering from atresia typically present with colic and absence of meconium passage (Bryant and Gaughan, 2005). In our case, the owner reported that meconium staining was observed, which we believe is most likely due to mucosal secretions present aboral to the abnormal segment. Louw (1964) observed that the persistent peristalsis of the distal intestinal segments caused them to empty, which could explain the staining seen by the owner. As it is unclear when the atresia developed during gestation, we cannot exclude that communication was once present, thereby yielding the possibility that a small amount of meconium could have passed into the intestinal parts aboral of the atretic segment.

Diagnostic imaging was used during examination of the foal. Plain abdominal radiographs are helpful in determining the location of intestinal obstruction in foals (Fischer *et al.* 1987). In the latero-lateral abdominal projection, the sternal flexure is positioned ventrally and more caudally to the diaphragmatic flexure (Campbell *et al.* 1984). The granular material in our case was interpreted as being located in the diaphragmatic flexure, since it reached the most cranioventral part of the abdomen. Since the atresia was located in the pelvic flexure, the material was actually in the sternal flexure. Positive contrast radiography could have supplemented the plain radiographic study. Oral administration of radiographic contrast and subsequent interpretation can require at least 3–8 h (Fischer *et al.* 1987) and is not always feasible depending on the condition of the foal. Retrograde contrast radiography is sensitive and specific for evaluating obstruction of the small colon or transverse colon (Fischer and Yarbrough, 1995), but less sensitive and specific for evaluation of the entire large colon (Young *et al.* 1992; Hunter and Belgrave, 2010). Had a contrast study been performed during initial investigation in our case, a more prompt diagnosis might have been reached, as it could have aided in distinguishing between the presumed meconium impaction and atresia. Ultrasonography is useful in evaluation of the neonate's abdomen (Bartmann *et al.* 2002), and in our case, ultrasonography showed almost complete paralytic ileus. The presence of a large amount of granular material in the cranial ventral abdomen accompanied complete paralytic ileus in a neonate, should alert the clinician to the possibility of atresia as an underlying cause in future cases.

A side-to-side colon anastomosis was performed using an ILA-100 anastomotic stapler to create a stoma large enough to allow passage of faecal material. Comparing the size of the ILA-100 to the size of the bowel, it can be argued that it is excessively large and using a smaller stapling device might have been more appropriate. However, the use of ILA-100 in this case did not cause intra-operative difficulties and was able to anastomose the two segments of large intestine seamlessly. In order not to constrict the lumen, the stapled stoma was not oversewn. This may have weakened the strength of the anastomosis, as the description of the side-to-side colon anastomosis in the adult colon includes oversewing the stapled stoma (Rakestraw and Hardy 2012).

The diameter of the LDC appeared narrower than the small intestine, which created a risk of post-operative obstruction. During the initial post-operative period, the

majority of the foal's diet consisted of milk, which was expected to pass easily. Therefore, the greatest risk of obstruction was anticipated to be when the foal would start to ingest more solid feeds. However, given the evidence that increases in large intestinal size occur as a relation to the amounts and type of feed ingested, it was anticipated that the size of the stenotic segment would rapidly increase (Lawrence and Lawrence 2009). Important influencing factors in the presented case is the fact that atretic segment was easily accessible for surgical correction, the involved colon segments were viable and easily apposed without tension, and no other congenital abnormalities or intestinal atresias were observed. This outlines important merits for consideration when performing surgical treatment of large colon atresia.

### Author's declaration of interest

No conflicts of interests have been declared.

### Ethical animal research

Not applicable.

### Source of funding

None.

### Authorship

All authors aided in case management and data interpretation. M.G.R. and S.S.H. performed the surgical correction. S.S.H. prepared the manuscript with aid from the other authors. All authors gave their final approval of the manuscript prior to submission.

### Manufacturers' addresses

<sup>1</sup>Konica Minolta Business Solutions Sweden AB, Kista, Sweden.

<sup>2</sup>Richter Pharma AG, Wels, Austria.

<sup>3</sup>Intervet AB, Stockholm, Sweden.

<sup>4</sup>Fresenius Kabi, Uppsala, Sweden.

<sup>5</sup>Orion Pharma AB, Danderyd, Sweden.

<sup>6</sup>Boehringer Ingelheim Animal Health, Malmö, Sweden.

<sup>7</sup>GE Healthcare Sweden AB, Stockholm, Sweden.

<sup>8</sup>Ratiopharm, Ulm, Germany.

<sup>9</sup>Covidien, Dublin, Ireland.

<sup>10</sup>Ethicon, Somerville, New Jersey, USA.

<sup>11</sup>N-vet AB, Uppsala, Sweden.

<sup>12</sup>Ceva Animal Health AB, Lund, Sweden.

<sup>13</sup>Triolab vet, Solna, Sweden.

<sup>14</sup>IDEXX, Wetherby, West Yorkshire, UK.

<sup>15</sup>Bayer AS, Copenhagen, Denmark.

### References

- Bartmann, C.P., Freeman, D.E., Glitz, F., von Oppen, T., Lorber, K.J., Bubeck, K., Klug, E. and Deegen, E. (2002) Diagnosis and surgical management of colic in the foal: literature review and a retrospective study. *Clin. Tech. Equine Pract.* **1**, 125–142.
- Biasutti, S., Dart, A.J., Dart, C.M., Uquillas, E. and Jeffcott, L.B. (2017) End-to-side anastomosis of the left ventral colon to the small colon in a neonatal foal with segmental agenesis of the large colon. *Aust. Vet. J.* **95**, 217–219.
- Bryant, J.E. and Gaughan, E.M. (2005) Abdominal surgery in neonatal foals. *Vet. Clin. N. Am. Equine Pract.* **21**, 511–535.
- Campbell, M.L., Ackerman, N. and Peyton, L.C. (1984) Radiographic gastrointestinal anatomy of the foal\*. *Vet. Radiol.* **25**, 194–204.

- Estes, R. and Lyall, W. (1979) Congenital atresia of the colon: a review and report of four cases in the horse. *J. Equine Med. Surg.* **3**, 495-498.
- Fischer, A. and Yarbrough, T. (1995) Retrograde contrast radiography of the distal portions of the intestinal-tract in foals. *J. Am. Vet. Med. Assoc.* **207**, 734-737.
- Fischer, A.T., Kerr, L.Y. and O'Brien, T.R. (1987) Radiographic diagnosis of gastrointestinal disorders in the foal. *Vet. Radiol.* **28**, 42-48.
- Hunter, B. and Belgrave, R.L. (2010) Atresia coli in a foal: diagnosis made with colonoscopy aided by N-butylscopolammonium bromide. *Equine Vet. Educ.* **22**, 429-433.
- Johnson, R. (1986a) Intestinal atresia and stenosis: A review comparing its etiopathogenesis. *Vet. Res. Commun.* **10**, 95-104.
- Johnson, R. (1986b) Intestinal atresia and stenosis: a review comparing its morphology. *Vet. Res. Commun.* **10**, 105-111.
- Lawrence, L.A. and Lawrence, T.J. (2009) Development of the equine gastrointestinal tract. In: *Advances in Equine Nutrition IV*, 4th edn., Ed: J.D. Pagan, Nottingham Univ. Press, Nottingham, England. pp 173-183.
- Louw, J.H. (1964) Investigations into the etiology of congenital atresia of the colon. *Dis. Colon Rectum* **7**, 471-478.
- Nappert, G., Laverty, S., Drolet, R. and Naylor, J. (1992) Atresia coli in 7 foals (1964-1990). *Equine Vet. J.* **24**, 57-60.
- Rakestraw, P.C. and Hardy, J. (2012) Large Intestine. In: *Equine Surgery*, 4th edn., Eds: J.A. Auer and J.A. Stick. Elsevier Saunders, St. Louis, Missouri. pp 454-494.
- Romano, J.E., Bryan, K., Ramos, R.S., Velez, J. and Pinedo, P. (2016) Effect of early pregnancy diagnosis by per rectum amniotic sac palpation on pregnancy loss, calving rates, and abnormalities in newborn dairy calves. *Theriogenology* **85**, 419-427.
- Romano, J.E., Pinedo, P., Bryan, K., Ramos, R.S., Solano, K.G., Merchan, D. and Velez, J. (2017) Comparison between allantochorion membrane and amniotic sac detection by per rectal palpation for pregnancy diagnosis on pregnancy loss, calving rates, and abnormalities in newborn calves. *Theriogenology* **90**, 219-227.
- Samuels, M.E., Majewski, J., Alirezaie, N., Fernandez, I., Casals, F., Patey, N., Decaluwe, H., Gosselin, I., Haddad, E., Hodgkinson, A., Idaghdour, Y., Marchand, V., Michaud, J.L., Rodrigue, M.-A., Desjardins, S., Dubois, S., Le Deist, F., Awadalla, P., Raymond, V. and Maranda, B. (2013) Exome sequencing identifies mutations in the gene *TTC7A* in French-Canadian cases with hereditary multiple intestinal atresia. *J. Med. Genet.* **50**, 324-329.
- Schlegel, F., Müller, W., Willer, S. and Busch, W. (1986) Die rektale Frühträchtigkeitsuntersuchung als auslösender Faktor der partiellen Kolonaplasie beim Rind. *Mh. Vet. Med.* **41**, 377-382.
- Schneider, J.E., Leipold, H.W., White, S.L. and Korsgaard, E. (1981) Repair of congenital atresia of the colon in a foal. *J. Equine. Vet. Sci.* **1**, 121-126.
- Turek, B. and Verhoeven, G. (2008) Atresia coli in a foal - case report. *Medycyna Weterynaryjna* **64**, 280-282.
- Young, R.L., Linford, R.L. and Olander, H.J. (1992) Atresia coli in the foal: a review of six cases. *Equine Vet. J.* **24**, 60-62.